

Postmortem Interval: A case of domestic canine indoor scavenging and mummification

*Sandra Call, MA, F-ABMDI
Travis County Medical Examiner's Office*

I, Sandra Call, am the only author and am responsible for all editorial decisions, reviews received and any revisions to be made. I have no closely related manuscripts that have been submitted for consideration. There are no conflicts of interest to my knowledge. This is my very first time submitting an article for publication. There is no copyrighted material in this submission.

Sandra Call
sandrajohnsoncall@yahoo.com
(808) 426-6917

Highlights

- Indoor domestic canine scavenger pattern differs from outdoor scavenger patterns.
- Domestic scavenging patterns reveal indicators of post-mortem interval.
- Studying domestic scavenging patterns provides insight into the position of death.
- Indoor domestic scavenging patterns are useful tools to medicolegal death investigators, pathologists, and law enforcement.

Abstract

Objective: As professional medicolegal death investigators and law enforcement officers, we are frequently confronted with domestic animal scavenging at death scenes. Despite the frequency of this phenomenon, there is very little research into the utility of analyzing domestic animal scavenging in the current literature. As with many studies focused on outdoor scavenging patterns, research of indoor patterns can be equally as informative to investigators in regard to the post-mortem interval. This case study aims to provide insight into the body's position at death and post-mortem interval using evidence of domestic canine scavenging. The author found that indoor canine patterns do not follow the published knowledge of outdoor scavenging patterns and aim to encourage future research into domestic scavenging patterns.

Key Words: Forensic Anthropology, Postmortem Interval, Animal Scavenging, Indoor Animal Scavenging, Domestic Scavenging

1. Introduction

Despite how frequently forensic investigators encounter evidence of canine scavenging of human remains, the occurrence is rarely reported in scientific literature. Most often, canine or canid scavenging in the indoor context is the result of domestic animals at the scene of a death without access to the outdoors or alternate sources of food. The dog owners often live alone, are estranged from family, are unemployed or work from home. Indoor scavenging patterns can be useful for determining the length of time between death and time of discovery. This span of time is referred to as the postmortem interval (PMI). The PMI is especially useful in cases where the time the decedent was last known alive is unknown or questionable. This case study will highlight how analyzing artifacts of decomposition and animal scavenging patterns aided in estimation of the PMI and the position the decedent was in at the time of death. While some research has reported cases of indoor animal scavenging ^{1,2,3,4} only one other case ⁴ has published results as extreme as the presented case.

2. Case Report

2.1 Scene Investigation

During the month of October, a local police department in Central Texas was contacted by a complainant who had been unable to reach a family member for an extended period of time. However, this was not unusual as the decedent was estranged from family. Law enforcement responded to the residence and found no signs of a disturbance. Forced entry was made into the home where skeletal remains were discovered with evidence of domestic canine scavenging to include fragments of human bone and animal feces. A midsize dog (approximately 75 pounds) was observed in the residence that appeared to be alive and well. Law enforcement noted bone fragments and animal feces throughout the residence (Fig 1). The fragments of skeletal material were dispersed across several rooms with the largest concentration of bone fragments in the master bedroom. A left and right tibia were observed in the bedroom with medical hardware suggestive of bilateral knee replacements.




Figure 1. Canine scat and bone fragments.

Upon closer examination of the skeletal elements on the living room floor, a skull, a fully articulated spinal column and right arm were observed. Mummified soft tissue covered the skull and anterior arm. On the carpet near the remains was a body shaped stain consistent with decomposition fluid (Fig. 2). A pair of leather cowboy boots were on either side of the stain. There were no skeletal elements or tissue within the boots. A bath towel was observed near the foot of the stain. There was no shredded or tattered clothing in the residence, suggesting that the decedent was nude at the time of death. All skeletal elements were collected and transported to the medical examiner's office for examination.

The resident of the home was reported to be reclusive and lived alone. The resident was never reported missing and was known to be a chronic abuser of illicit substances and alcohol. The residence was a single-story home that was searched extensively for evidence pointing to a probable cause and manner of death. The indoor ambient temperature

was 78 degrees Fahrenheit according to the digital thermostat within the residence. Evidence of alcohol consumption and



Figure 2. Decomposition stain in the living room.

illicit substance abuse was noted. Prescription medications were also located within the bathroom. There was running water in the shower and the stop valve remained open. There were no signs of or remnants of dog food, or dog food containers. An empty dog dish was observed on the back porch but was not accessible to the dog. There were no weapons or suicide notes on the scene. There were no concerns of foul play.

2.2 Pathological and Anthropological Analysis

Upon examination by the pathologist, no obvious indicators of cause of death were observed. There were no penetrating defects, or sharp force trauma noted to the remains. The skeletal elements were heavily scavenged with obvious gnawing to the proximal and distal ends of the long bones and sternal rib ends. An anthropological examination was requested. Anthropological analysis aimed to assist in making positive identification, identify any signs of perimortem trauma indicative of cause of death, and to estimate the postmortem interval.

Mummified tissue of the head and anterior right arm were noted. The facial tissue to the right side of the face appeared compressed suggesting contact with a hard surface for an extended

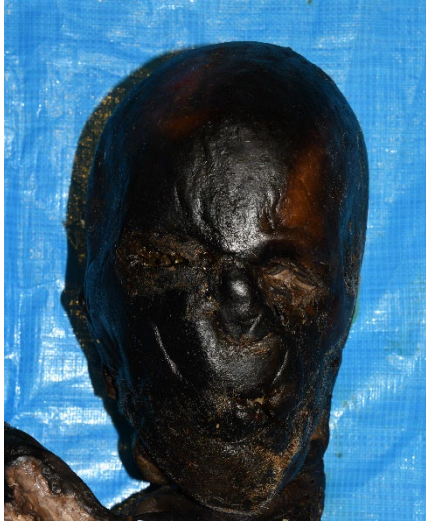

Figure 3. Mummified facial tissue.

period of time (Fig 3). The remaining skeletal elements had been heavily scavenged with little to no soft tissue remaining. The mummified tissue was removed, and the bones were cleaned using warm water and towels. The anthropological analysis began with the skeletal inventory. The remains consisted of a complete cranium and mandible. Elements of the axial and appendicular skeleton were present with the exception of the sternum, left humerus, radius and ulna, all bones of the left hand, the bilateral patellae, the bilateral fibulae, and all bones of the bilateral feet. All skeletal elements that were present exhibited none to heavy canine scavenging to include gnawing and punctures at the proximal and distal ends of the long bones of the lower extremities. Characteristics of canid scavenging are easily recognizable secondary to their distinct dentition. Canine dentition includes four quadrants consisting of three bevel-shaped incisors, one

canine, four premolars and two molars on the maxilla, and four premolars and three molars on the mandible⁵. Their dentition is designed for biting, shearing, and tearing meat. Punctures are the result of biting down while linear indentations are the result of shearing and gnawing⁵.

The biological profile consists of the estimated sex, ancestry, age, stature, and any individualistic characteristics of the decedent. The pelvis is the most reliable skeletal region to determine biological sex. However, the pelvis was heavily scavenged rendering the pelvis unfit for analysis. Non-metric features of the skull were consistent with that of a male.^{6,7} The overall appearance was robust with a pronounced supraorbital margin, nuchal crest, and mastoid processes. Cranial measurements paired with morphoscopic features were subjected to discriminant function analysis to estimate ancestry^{6,8}. Results of all analysis estimated the decedent to be a Caucasian male. Due to significant postmortem changes of the skeletal elements, cranial sutures were used to estimate age. The decedent was estimated to be greater than 45 years of age. The maximum length of the right radius was analyzed and resulted in an estimated stature between 62.8 and 70.6 inches.^{8,9} The decedent exhibited extensive dental modifications to include caps on the bilateral mandibular second molars, and other significant alterations. Serial numbers were recorded from medical hardware to the bilateral tibiae. While there was extensive evidence of canine scavenging on the proximal and distal ends of all long bones recovered with the exception of the right humerus, radius ulna and four carpals, some skeletal elements were consumed completely.

2.3 Identification/Cause and Manner of Death

Forensic odontology was later employed to positively identify the decedent. The demographic estimations made by the biological profile were consistent with known information about the decedent's positive identification. Postmortem dental x-rays were performed and antemortem dental records were obtained. The decedent had a medical history of hypertension and a social history of illicit substance abuse. He had no known history of suicidal ideations or attempts. Evidence of illicit substances was observed on scene and forensic toxicology was requested. The cause of death is currently pending. There is no evidence that the dog attacked or caused the decedent's death.

3. Discussion

3.1 PMI

Estimating the postmortem interval (PMI) is one of the most challenging tasks for forensic anthropologists due to the number of intrinsic and extrinsic variables involved in the decomposition process; however, decomposition of living material is assumed to follow a predictable pattern after death. Traditional methods for estimating the PMI involve observing the stages of the decomposition process such as bloating, skin slippage, and insect activity¹⁰. This case was especially challenging due to the severity of animal scavenging. However, some tissue, animal scavenging, and a decomposition stain in the living room carpet provided some evidence of the sequence of events. Establishing an estimated postmortem interval can help determine if the decedent's last known contact with family and neighbors is consistent with evidence observed at the scene.

In the living room, a large brown stain in the shape of a human body was observed (Fig.2). The indoor ambient temperature recorded at the scene was 78 degrees Fahrenheit. The exact time of which animal scavenging takes place is not known and has been attributed to the animal's level of hunger and availability of alternate sources of food^{6,3,11}. The stain was made up of decomposition fluid and reflected a complete human form; this suggested that the decedent was not immediately disarticulated by his pet dog. The decedent was down long enough to begin the putrefactive process where the tissues and organs begin to breakdown and liquify. This stage of the decomposition process typically takes place 24 to 48 hours after death¹². This process is accelerated in warmer environments.

Remaining tissue of the arm and head was completely mummified. In a study that examined postmortem changes in an indoor setting, complete mummification of the head and extremities in similar temperatures was observed between one to two months after death¹³. The only other case study in the literature that illustrates near complete consumption of a single decedent by two midsized dogs occurred over a four-week period⁴. In this present case however, only a single midsized dog was present. Based on previous literature and the predictable patterns of canid scavenging and decomposition, the PMI is estimated to be between six and eight weeks.

3.2 Scavenging Pattern and Found Position

Researchers have found that specific patterns are involved in canine scavenging beginning with the face and neck. Scavenging of the face typically begins with consumption of the lips and nose followed by the trunk, and upper and lower extremities.^{2,14} Forty-one cases involving indoor scavenging were reviewed by² with 73% exhibiting the face as the most scavenged region. This pattern was also demonstrated while observing canine scavengers in the outdoor context¹⁴. While the literature reports that the face and neck is the most scavenged region, in this case, the face showed no evidence of canine predation, and the tissue of the head and anterior right arm was completely mummified. The expected sequence of scavenging was not consistent with typical canid scavenging patterns. However, the decedent's face appeared flattened on the right side, which suggested contact with a flat surface for an extended period of time. Given the mummified, flattened appearance of the facial tissue and lack of animal predation, it is estimated that the decedent was likely lying face down placing his face in contact with the flooring. This would mean that the facial tissue was not easily accessible. This pattern would also explain the preservation on the right upper extremity. The decedent's right arm was likely tucked underneath him and was not scavenged in the typical expected pattern outlined by other researchers. The right arm was also near the lower border of the living room couch, creating another layer of difficulty, while other parts of the body were easily accessible. According to Colard et al. (2015) following the initial consumption of soft tissue such as the face, and trunk, the extremities are then disarticulated and scattered throughout the enclosed context within two to four months. In this case, the extremities had been disarticulated with the largest cluster of bony material inside the master bedroom².

4. Conclusions

Based on investigation of the scene, examination of the remains, and review of the literature, the decedent likely died approximately six to eight weeks prior to discovery. The complete mummification of the cranial and upper extremity tissue in an enclosed environment of 78 degrees Fahrenheit and the typical pattern of domestic scavenging were key factors to estimating when the decedent died. The decedent had begun the decomposition process in the living room on the carpet prior to the animal scavenging process. Additionally, a shopping receipt dated mid-July was located in the kitchen trashcan. The dated receipt in the trash can was consistent with the date the decedent was last known to be responsive and aligned with the sequence of decomposition. The decedent's downed position made his face and anterior right arm inaccessible to the canine and thus explains the unconventional pattern of canine scavenging. This paper is one of few in the literature to demonstrate the use of scavenging patterns to estimate the decedent's position at the time of death highlighting another use for such research involving animal scavenging in the indoor context. The literature on such case studies is scarce and needs to be expanded upon to fully explore the utility of examining indoor scavenging patterns.

References

1. Clark, M. A., Sandusky, G. E., Hawley, D. A., Pless, J. E., Fardal, P. M., & Tate, L. R. (1991). Fatal and Near-Fatal Animal Bite Injuries. *Journal of Forensic Sciences*, 36(4), 13146J. <https://doi.org/10.1520/jfs13146j>
2. Colard, T., Delannoy, Y., Naji, S., Gosset, D., Hartnett, K., & Bécart, A. (2015). Specific Patterns of Canine Scavenging in Indoor Settings. *Journal of Forensic Sciences*, 60(2), 495–500. <https://doi.org/10.1111/1556-4029.12684>
3. Rossi, M. L., Shahrom, A. W., Chapman, R. C., & Vanezis, P. (1994). Postmortem Injuries by Indoor Pets. *The American Journal of Forensic Medicine and Pathology*, 15(2), 105–109. <https://doi.org/10.1097/00000433-199406000-00004>
4. Steadman, D. W., & Worne, H. (2007). Canine scavenging of human remains in an indoor setting. *Forensic Science International*, 173(1), 78–82. <https://doi.org/10.1016/j.forsciint.2006.11.011>
5. Haglund, W. D., Reay, D. T., & Swindler, D. R. (1988). Tooth Mark Artifacts and Survival of Bones in Animal Scavenged Human Skeletons. *Journal of Forensic Sciences*, 33(4), 12521J. <https://doi.org/10.1520/jfs12521j>
6. Buikstra, J. E., & Ubelaker, D. H. (1994). Standards for Data Collection from Human Skeletal Remains: Proceedings of a Seminar at the Field Museum of Natural History (Arkansas Archeological Survey Research Report) (12154th ed.). Arkansas Archeological Survey.
7. Walker, P. L. (2008). Sexing skulls using discriminant function analysis of visually assessed traits. *American Journal of Physical Anthropology*, 136(1), 39–50. <https://doi.org/10.1002/ajpa.20776>
8. Ousley, S. D., & Jantz, R. L. (2012). Fordisc 3 and Statistical Methods for Estimating Sex and Ancestry. *A Companion to Forensic Anthropology*, 311–329. <https://doi.org/10.1002/9781118255377.ch15>
9. Meindl, R. S., & Lovejoy, C. O. (1985). Ectocranial suture closure: A revised method for the determination of skeletal age at death based on the lateral-anterior sutures. *American Journal of Physical Anthropology*, 68(1), 57–66. <https://doi.org/10.1002/ajpa.1330680106>
10. Clark, C. M. A., Worrell, M. B., & Pless, J. E. (1997). Postmortem changes in soft tissues. In W. D. Haglund & M. H. Sorg (Eds.), *Forensic taphonomy : the postmortem fate of human remains* (pp. 151–164). CRC Press.
11. Rothschild, M. A., & Schneider, V. (1997). On the temporal onset of postmortem animal scavenging. *Forensic Science International*, 89(1–2), 57–64. [https://doi.org/10.1016/s0379-0738\(97\)00112-6](https://doi.org/10.1016/s0379-0738(97)00112-6)

12. Matuszewski, S., & Mądra-Bielewicz, A. (2019). Post-mortem interval estimation based on insect evidence in a quasi-indoor habitat. *Science & Justice*, 59(1), 109–115.
<https://doi.org/10.1016/j.scijus.2018.06.004>
13. Leccia, C., Alunni, V., & Quatrehomme, G. (2018). Modern (forensic) mummies: A study of twenty cases. *Forensic Science International*, 288, 330.e1-330.e9.
<https://doi.org/10.1016/j.forsciint.2018.04.029>
14. Haglund, W. D., Reay, D. T., & Swindler, D. R. (1989). Canid Scavenging/Disarticulation Sequence of Human Remains in the Pacific Northwest. *Journal of Forensic Sciences*, 34(3), 12679J. <https://doi.org/10.1520/jfs12679j>